

Chapter 14

Lower Limb

Conditions

Aetiological classification

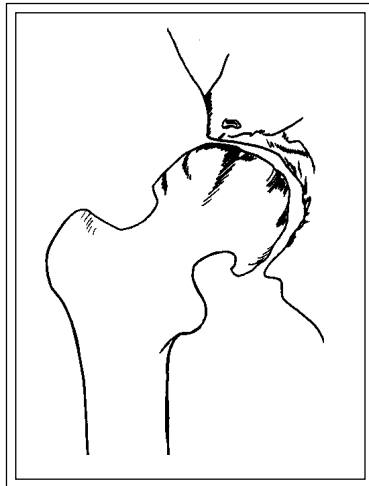
Anatomical classification

Hip and femur

Knee and tibia

Ankle and hindfoot

Forefoot and toes



Classification

Aetiological Classification

Congenital abnormalities

Dwarfism - achondroplasia
 cretinism
 gargoylism
Amelia and phocomelia
CDH and protrusio acetabuli
Coxa vara and valga
Genu varum, valgum and recurvatum
Talipes
Congenital vertical talus
Talocalcaneal - navicular bar
Pes planus and cavus
Metatarsus primus varus
Macroductyly
Syndactyly and webbing

Neoplasia

Benign - bony
 cartilaginous
 soft tissue
Malignant - primary - bony
 cartilaginous
 soft tissue
 secondary

Trauma

Soft tissue injuries - tendons and
ligaments
 nerves
 vessels
Subluxation and dislocation
Fractures

Infection

Soft tissue
Bone
Joint

Arthritis

Degenerative (primary or secondary osteoarthritis)
Autoimmune
Metabolic
Haemophilic arthropathy

Paralysis

Cerebral
cerebral palsy
neoplasia
vascular conditions
trauma
Spinal
disc protrusion
fractures
spina bifida
syringomyelia
poliomyelitis
Peripheral nerves
peripheral neuritis and toxins
diabetic neuropathy

Anatomical Classification

Hip and femur

Knee and tibia

Ankle and hindfoot

Forefoot and toes

Aetiological Classification

Most conditions of the lower limb are discussed in detail in the relevant sections of this book. It is the purpose of this chapter to discuss other conditions which do not fall into any of the other categories. Conditions discussed in other chapters are given below.

Congenital abnormalities

Developmental abnormalities include limb defects, such as overgrowth and fusion, as well as congenital dislocation of the hip and bilateral coxa and genu vara and valga.

They also include ankle and foot conditions such as talipes equino varus, congenital vertical talus, metatarsus primus varus and other foot deformities.

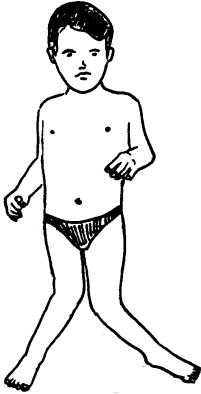
Generalised developmental conditions include achondroplasia and polyostotic fibrous dysplasia.

Neoplasia

Developmental tumours include multiple osteochondroma (diaphyseal aclasis) and benign bone cysts as well as multiple neurofibroma. Most tumours, however, are of unknown origin and develop in childhood or adult life. They range from benign tumours such as aneurysmal bone cysts, eosinophilic granuloma and non-ossifying fibromata, to malignant tumours such as osteogenic

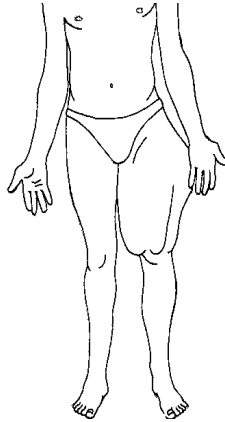
Aetiological Classification

Congenital abnormalities



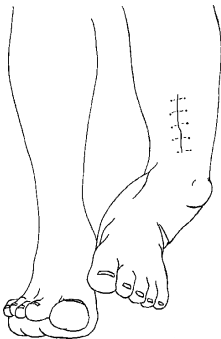
Genu valgum

Neoplasia



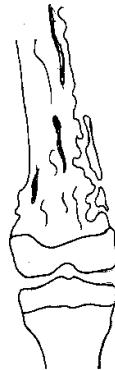Osteogenic sarcoma

Trauma



Deformity due to tibial trauma

Infection



X-ray appearance of osteomyelitis

sarcoma, chondrosarcoma and Ewing's sarcoma.

Trauma

Various chapters discuss both recent and old injuries to bones, ligaments, tendons and other structures. It is especially important to consider trauma as an aetiological factor when dealing with swellings associated with the bone, as the differential diagnosis includes both inflammatory and neoplastic conditions.

Infection

A low grade osteomyelitis of the femur or tibia, or a pyogenic arthritis of the hip or knee sometimes is difficult to differentiate from tumours or other inflammatory conditions such as rheumatoid arthritis.

Arthritis

Osteoarthritis of the hip and knee is common and rheumatoid arthritis can occur in major joints as well as in the hands and feet. Arthritis may also be due to gout, haemophilia and other non-infective conditions.

Paralysis

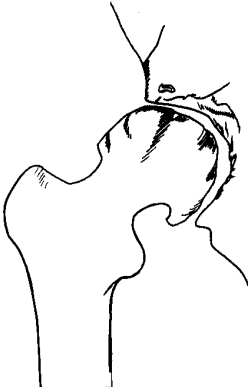Paralysis of the lower limb may be caused by cerebral, spinal cord or peripheral nerve lesions or a combination of these. They include cerebral palsy, head injuries, spina bifida and poliomyelitis.

Miscellaneous conditions

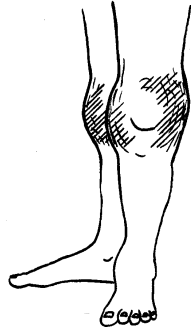
A miscellaneous group of conditions includes Paget's disease, hallux valgus and plantar fasciitis.

Aetiological Classification

Arthritis

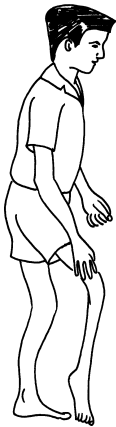

X-ray appearance of
osteoarthritis



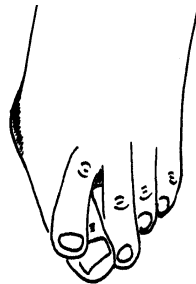Rheumatoid arthritis

Paralysis



Poliomyelitis

Miscellaneous conditions



Hallux valgus

Anatomical Classification

Hip and femoral conditions

Paget's disease

Paget's disease affecting the femur is fairly common and may cause overgrowth, bowing, pathological fractures and, rarely, osteogenic sarcoma.

Infection

Secondary osteomyelitis is more common than primary osteomyelitis and usually follows operative internal fixation of hip or femur or open femoral fractures. Pyogenic arthritis of the hip is still fairly common, particularly in children and is usually due to blood borne spread.

Snapping hip

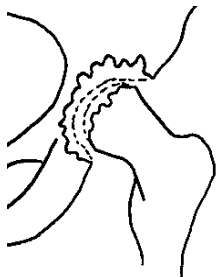This is a fairly common condition resulting from the ilio-tibial band catching over the greater trochanter. It may be due to unaccustomed exercise and can cause inflammation of the bursa over the greater trochanter.

This condition will usually respond to rest and anti-inflammatory drugs. It occasionally requires division of the ilio-tibial band in the mid thigh.

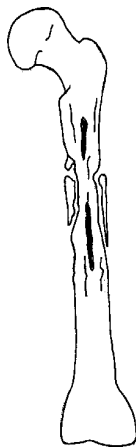
Tom Smith's disease and Girdlestone's arthroplasty

Tom Smith's disease is a septic arthritis of a major joint occurring in the first year of

Hip and Femoral Conditions



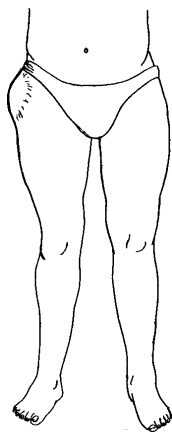
X-ray appearance
of an infected hip



X-ray appearance
of osteomyelitis



X-ray appearance of
Paget's disease



Trochanteric
bursitis

life and leading to complete destruction of the joint. It is now uncommon except in developing countries.

A similar, but more common situation, occurs following Girdlestone's procedure. This is an excision arthroplasty of the hip which is performed following an unresolved infection complicating total hip arthroplasty.

Both arthroplasties may present as a telescoping unstable hip requiring later hip replacement.

Avascular hip conditions

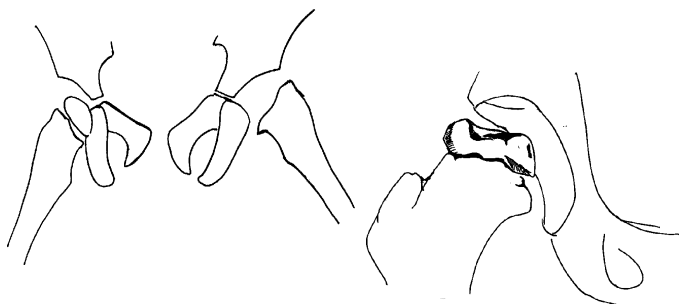
Perthes' disease is due to avascular changes in the head of the femur. It occurs most commonly between the ages of 5 and 10 years. It is discussed in more detail in Chapter 7. Avascular changes of the head of the femur also occur in sickle cell disease and in slipped epiphyses in children. In adults, avascular changes may follow hip dislocation or subcapital fractures of the femur.

These changes also occur in chronic alcoholism and following prolonged glucocorticosteroid therapy, especially in patients who have undergone renal or other organ transplantation.

Slipped capital femoral epiphysis

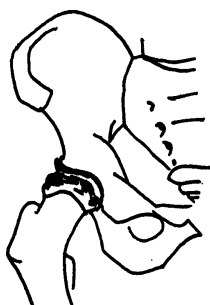Slipped epiphysis is discussed in more detail in chapter 7 and occurs most commonly between the ages of 10 and 15 years. Although trauma plays a part in some cases, in many children an imbalance of sex and growth hormones is thought to be responsible.

Hip and Femoral Conditions

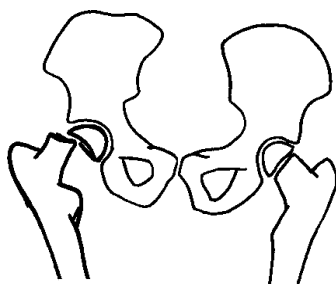


X-ray appearance of Tom
Smith's disease and
Girdlestone's
arthroplasty

X-ray appearance of
Perthes' disease



X-ray appearance of
avascular necrosis



X-ray appearance of
slipped capital femoral
epiphysis

Knee and tibial conditions

Baker's cyst and semimembranosus bursa

This is a cystic swelling in the popliteal fossa usually due to synovial outpouching from an osteoarthritic knee. Other causes of chronic arthritis with effusion in the knee can also lead to a Baker's cyst.

The differential diagnosis of popliteal swellings includes lymph nodes, a popliteal aneurysm and a semimembranosus bursa.

Treatment is of the underlying condition and occasionally excision of the cyst.

Bursitis

Prepatellar bursitis (housemaid's knee) is due to traumatic or infective inflammation of the prepatellar bursa, that is, the bursa in front of the knee.

Infrapatellar bursitis (clergyman's knee) has similar causes.

A suprapatellar bursa is an outpouching of synovial fluid and synovia in the knee itself. It is particularly prominent in chronic osteoarthritis, and also occurs with any knee effusion.

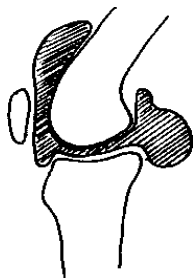
Osgood-Schlatter's disease

This is a traction osteochondritis of the tibial tubercle and is most common in boys of about 14 years of age. Such traction injuries often result from kicking footballs or jumping.


There is tenderness and bony swelling over the insertion of the ligamentum patellae and X-ray often shows elevation and sometimes fragmentation of the tibial tubercle.

Treatment is rest from sport and sometimes a detachable splint behind the knee.

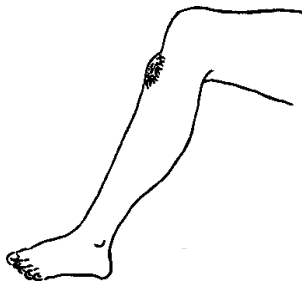
Knee and Tibial Conditions



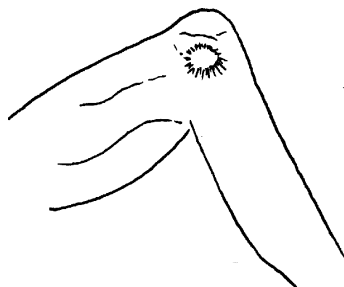
X-ray arthrogram of
a Baker's cyst



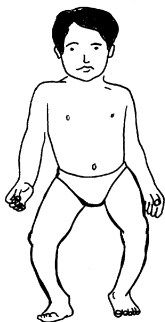
Enlarged prepatellar
bursa



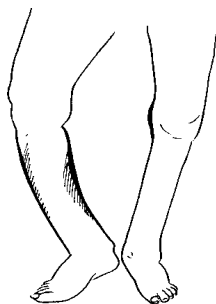
Osgood-Schlatter's
disease



Lateral meniscal
cyst



Genu varum



Paget's disease

Cyst of the lateral meniscus

This is probably a degeneration of the lateral meniscus following trauma rather than a congenital cyst. There is a tender cystic swelling, usually situated over the middle of the lateral meniscus.

Treatment used to be a total meniscectomy but local excision of the cyst alone is adequate.

Deformities of the knee

Premature fusion of the medial femoral or tibial epiphysis will produce a genu varus while early fusion of the lateral femoral or tibial epiphysis will lead to a genu valgum (Chapter 7). Unbalanced paralysis of the knee extensors or flexors may lead to flexion deformity or genu recurvatum.

Degenerative changes in the medial and lateral joint of the knee may lead to narrowing of the joint and a small degree of genu varum or valgum. Swelling of the knee in arthritis of any cause will lead to limitation of full extension and often flexion as well.

Paget's disease of the tibia

Paget's disease is discussed in further detail in Chapter 11. There is usually bowing and thickening of the tibia and pathological fractures may occur. Osteogenic sarcoma is a rare complication. High-output cardiac failure may occur in extensive Paget's disease, as the affected bone is highly vascular.

Osteochondritis dissecans

Osteochondritis dissecans usually involves the lateral side of the medial femoral condyle and occurs most commonly in adolescent boys. It usually results from trauma to the cartilage with avascular changes in the underlying bone. As a result an area of cartilage about 5-10 mm in diameter, together with the underlying bone becomes avascular. This area may detach and form a loose body in the joint, which may catch in the joint and cause it to lock.

The usual treatment is to re-attach the partially loose fragment with a recessed screw before it detaches, or excise it once it is free in the joint.

Avascular necrosis of one or both femoral condyles may occur after steroid therapy, such as in chronic asthma and renal transplantation.

Treatment is excision of the avascular segment and drilling and revascularising the remainder of the condyle. Occasionally total knee replacement is required.

Meniscal and ligamentous injuries

These may cause pain and swelling of the knee with instability and eventually osteoarthritis. Early arthroscopic excision of detached fragments or open repair is often indicated.

Ankle and hind foot conditions

Tendonitis

Tendonitis on the medial side of the ankle is usually due to inflammation of the tibialis posterior tendon sheath and on the lateral side to inflammation of the sheaths of the peroneal tendons.

Posteriorly the sheath of the tendo calcaneus may become inflamed by overuse of the tendon, by rubbing on the back of a shoe or by minor tears of the fibres of the tendon itself. Partial or complete rupture of the tendon may also occur.

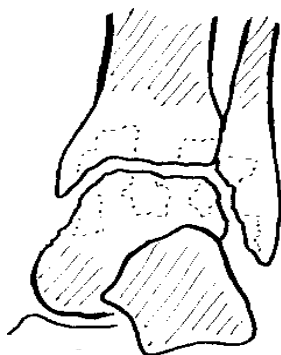
Clinically there is tenderness and often swelling over the sheath of the relevant tendon and usually pain on stressing the tendon.

Treatment includes 'resting the tendon' with an elevated heel on both shoes, the application of ice packs and elevation of the leg in the acute stage. In chronic tendonitis deep heat, massage and sometimes injections of hydrocortisone and local anaesthetic into the tendon sheath (not the tendon) may be necessary. Occasionally incision of the tendon sheath may be required. Rupture of the plantaris tendon may also occur and lead to a sudden sharp pain in the mid calf. The treatment is the same as for a tendonitis of the tendo Achillis.

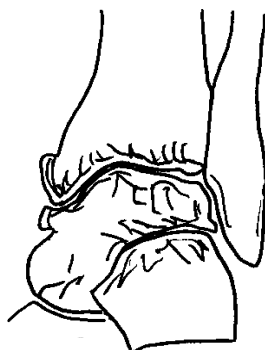Painful heel

Pain under the heel is usually due to a plantar fasciitis, possibly following bruising of the heel. It may be associated with a calcaneal spur seen on X-ray but this is often unrelated to the pain. The heel sometimes becomes painful in chronic infections, in rheumatoid arthritis and in other inflammatory diseases.

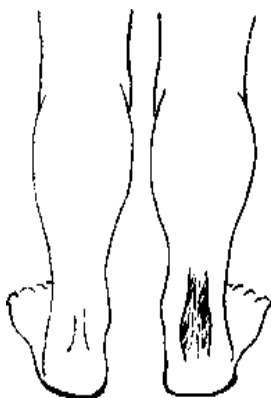
Ankle and Hind Foot Conditions



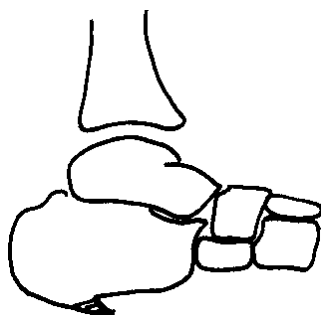
X-ray appearance of
rheumatoid arthritis



X-ray appearance of
osteoarthritis



Tendinitis



X-ray appearance
of a calcaneal
spur

On examination there is usually localised tenderness under the point of the heel just in front of the calcaneal tuberosity.

Treatment involves treating the cause, if obvious, as well as a heel pad to reduce the pressure. Occasionally physiotherapy or an injection of hydrocortisone may be necessary. The differential diagnosis includes a fracture of the calcaneus and osteomyelitis.

Longitudinal arch conditions

Clawing or cavus of the foot may be associated with a neurological condition such as poliomyelitis, spina bifida or Friedreich's ataxia. More commonly, however, it is idiopathic. The treatment of cavus feet is the treatment of the underlying cause and occasionally operative correction of the deformity.

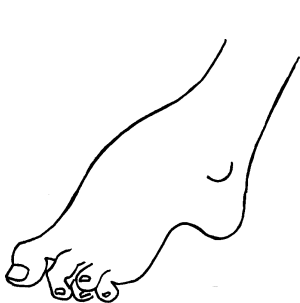Flattening of the longitudinal arch may be idiopathic in young patients or secondary to poor intrinsic muscles in elderly and overweight patients. Spasmodic flat feet with peroneal muscle spasm occur occasionally, with a congenital calocalcaneo-navicular bar.

The treatment of painful flat feet due to poor intrinsic muscles is intrinsic reduction and adequate footwear as well as a longitudinal arch support. Spasmodic flat feet may sometimes require operative fusion of the subtaloid joints.

Paralysed foot

Paralysis of the foot, such as in poliomyelitis or common peroneal or sciatic nerve damage, may lead to a 'foot drop' and also to a fixed equinus of the ankle. This may necessitate elongation of the tendo Achillis followed by a below knee caliper or alternatively an arthrodesis of the subtaloid joints may be needed.

Ankle and Hind Foot Conditions



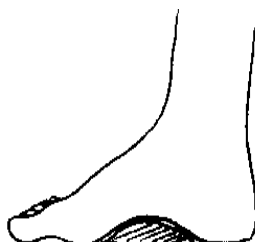**Pes cavus and
clawed toes**



Paralysed foot



Pes planus



Arch support

Spastic paralysis from an upper motor neurone lesion may also require a below knee caliper, again sometimes preceded by elongation of the tendo Achillis.

Forefoot and toe conditions

Classification of forefoot conditions can be divided into those affecting the plantar surface, the dorsum and the sides of the feet. Deformities of the toes are often associated with these conditions.

Plantar surface of foot

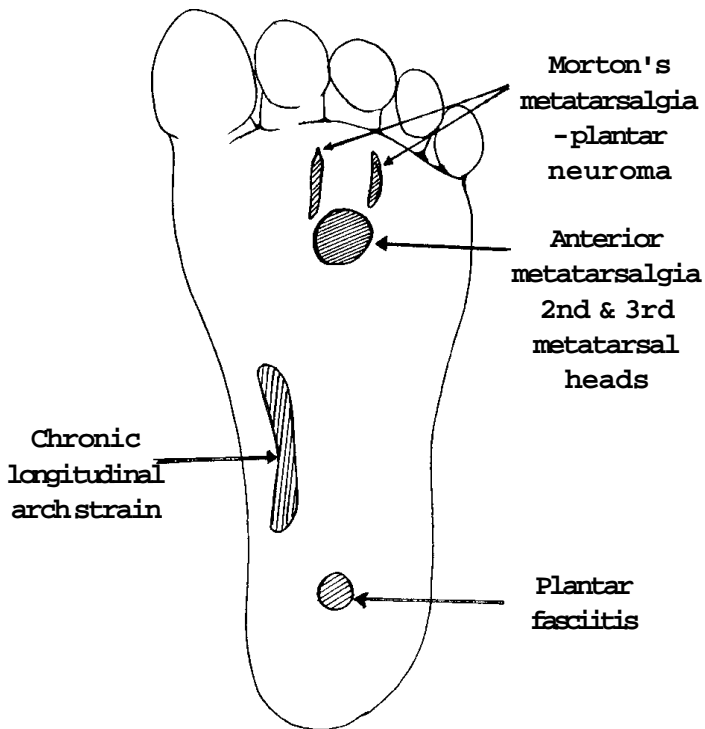
Anterior metatarsalgia

This is a painful area under the metatarsal heads, commonly the 2nd, 3rd, and 4th. It is usually due to weakening of the dynamic muscular structure of the foot. It is often associated with obesity, poor muscle tone, clawing of the toes and sometimes various neurological conditions such as poliomyelitis, leading to weakness of the intrinsic muscles.

Morton's metatarsalgia (plantar neuroma)

This is due to irritation followed by enlargement of a plantar digital nerve, usually between the 2nd and 3rd or 3rd and 4th metatarsal heads. The patient complains of pain in the forefoot, often at night when the feet are warm, and also while walking. The condition is often associated with an anterior metatarsalgia. During examination the main tender area can usually be pinpointed to lie between the metatarsal heads rather than under them as is the case in anterior metatarsalgia. The pain is usually worse on lateral compression of the forefoot which compresses an enlarged neuroma between the metatarsal heads. There may also be numbness between the toes supplied by the relevant cutaneous nerve.

Forefoot and Toe Conditions



Plantar surface of the foot

Treatment of both anterior metatarsalgia and a digital neuroma is an anterior metatarsal pad or button placed just *behind* the metatarsal heads, plus good footwear and intensive muscle reduction. If this is not successful the plantar neuroma should be excised. In the case of anterior metatarsalgia correction of claw toes by subcutaneous tenotomy of the extensor tendons, transfer of flexor tendons to the extensor or arthrodesis of the proximal interphalangeal joints of the clawed toes may be carried out. Occasionally excision of a prominent 2nd or 3rd metatarsal head may be necessary.

Dorsum of foot and toes

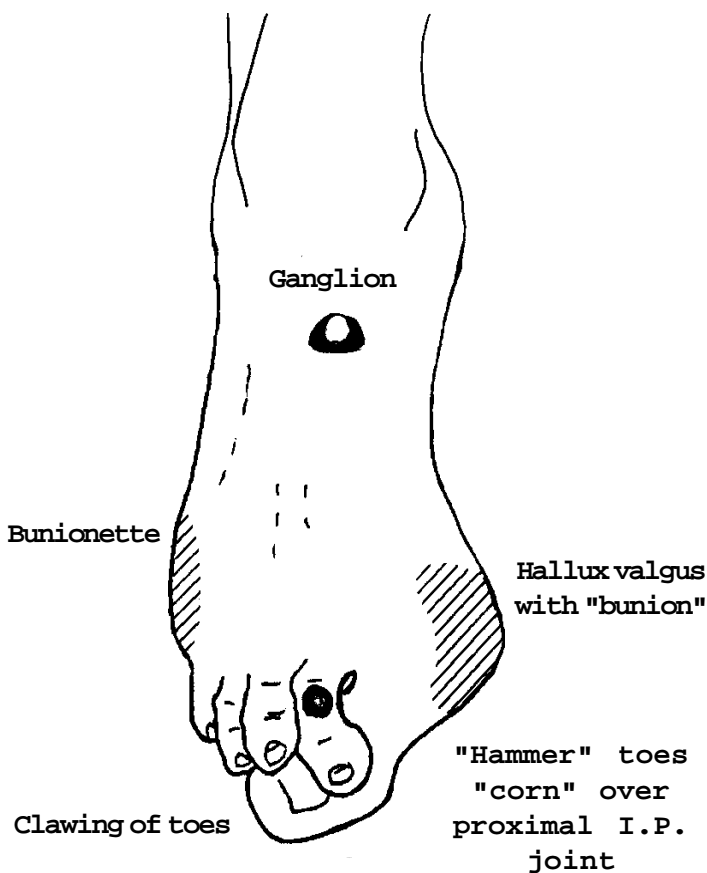
March fracture

This condition is often missed. It is a stress fracture, usually of the necks of the 2nd and 3rd metatarsals, due to unaccustomed walking, sometimes seen in new army recruits. The tender area, however, is over the dorsum rather than the plantar aspect of the metatarsals. X-rays show a fine crack in the bone which may be difficult to see at the time of injury. Three to four weeks later callus formation around the fracture confirms the diagnosis, much to the embarrassment of the treating doctor if the initial fracture was overlooked. The initial treatment is rest followed by gradually increased weight-bearing, graded exercises and walking.

Hallux valgus

This is a valgus deformity of the big toe which may be combined with or due to a varus deformity of the first metatarsal (metatarsus primus varus). The cause is often a combination of a genetic predisposition together with tight shoes. This causes a prominence of the first metatarsal head on the

Forefoot and Toe Conditions



Dorsum of the foot

medial side of the foot which gradually leads to an exostosis. Overlying this prominence is a bursa which may become enlarged and inflamed to form a 'bunion'.

Treatment initially should be a trial of wider shoes and small pads to relieve the pressure over the prominent metatarsal head plus exercises for the intrinsic muscles of the feet. Operative treatment can include osteotomy of the first metatarsal to correct the valgus deformity, intrinsic muscle transfer, excision of the proximal part of the proximal phalanx (Keller's operation), or arthrodesis of the first metatarsophalangeal joint.

Hallus rigidus

This is due to osteoarthritis of the first metatarsophalangeal joint. It is often secondary to trauma and leads to a fairly stiff joint which causes pain, particularly on dorsiflexion. X-rays usually show a diminution of the joint space and osteophyte formation. If attempts at conservative treatment, including firm soled shoes, a rocker sole or a metatarsal bar on the sole of the shoe fail to prevent excessive movement of the joint, an arthrodesis of the first metatarsophalangeal joint may be necessary.

Exostoses

An exostosis of the head of the 5th metatarsal is referred to as a bunionette. This condition may be associated with valgus or other foot deformities and may require excision if conservative measures fail. Other exostoses, including those over the base of the 5th metatarsal, are treated with better footwear, pads, and occasionally operative excision.

Clawing of toes

Clawing or overriding of the 2nd to 5th toes is common and is often associated with other foot deformities, or weakness of the intrinsic muscles of the feet. The 2nd toe may over-

ride a hallux valgus while the 5th toe may override the 4th. In the latter case this may be due to a symmetrical, congenital deformity. A neurological basis for clawing must always be eliminated, such as poliomyelitis, peripheral neuritis or spina bifida (especially if associated with a cavus foot and sensory deficit or motor weakness). Many cases, however, occur in elderly, overweight women with poor intrinsic muscles.

Flexed proximal and distal interphalangeal joints may cause pressure and tenderness over the end of the flexed toes which press on the shoe or ground. Correction of this condition includes appropriate footwear, intrinsic muscle reduction, 'corn' pads and occasionally operation, as discussed under anterior metatarsalgia. Other foot conditions, including exostoses, may occur elsewhere due to rubbing of shoes.

Ganglion

This is a cystic swelling filled with glairy fluid and associated with a joint. Excision of an exostosis or ganglion may be necessary if conservative measures fail and if the condition is symptomatic.

Miscellaneous conditions

The differential diagnosis of foot conditions includes congenital deformities such as talipes equino varus and spasmodic flat feet (often associated with a talocalcaneonavicular bar), tumours, trauma, infections and arthritis. All these conditions, as well as osteoarthritis, rheumatoid arthritis, gout and paralytic conditions are discussed elsewhere in this book.

